

## 10. AXILLARY BLOCK

### INTRODUCTION

Except for single nerve blocks in the arm and forearm, the axillary block is the most distal block performed on the brachial plexus. Because of the distal location (in contrast to other brachial plexus approaches), the axillary block has negligible risks of the respiratory compromise secondary to pneumothorax or phrenic nerve blockade. In addition, the peripheral location permits adequate arterial tamponade to be applied if an inadvertent puncture occurs.

### ANATOMY

At this level, the plexus has divided into its terminal nerve branches, with two major nerves originating from each cord. The lateral cord divides into the musculocutaneous nerve and the

lateral portion of the median nerve, the medial cord divides into the ulnar nerve and the medial portion of the median nerve, and the posterior cord divides into the radial nerve and axillary nerve (Figures 10-1 and 10-2). The median, ulnar, and radial nerves all travel with the axillary artery within the axillary sheath; however, the musculocutaneous nerve travels separately within the belly of the coracobrachialis muscle. For this reason, the musculocutaneous nerve must be blocked separately during an axillary nerve block.

This block should only be performed for surgeries involving the hand or forearm (Figure 10-3). A supraclavicular or infraclavicular nerve block should be used for surgeries involving the upper arm or elbow to obtain more complete coverage of the upper extremity. Any patient who is unable to abduct their arm more than 45° at the shoulder is not an appropriate candidate for the axillary block.

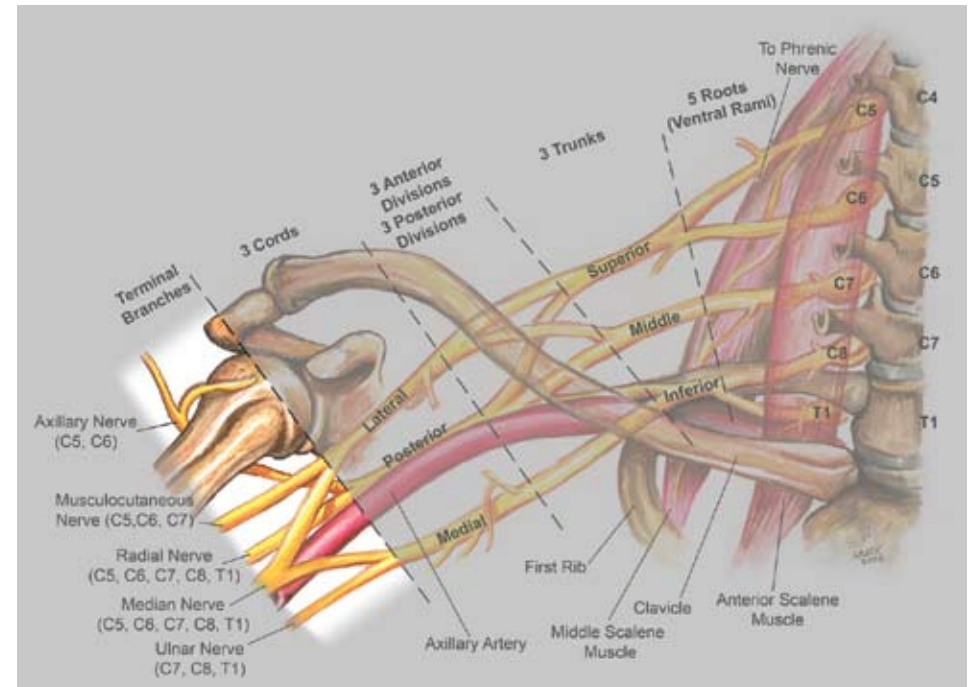


Figure 10-2

Figure 10-1. Dermatomes anesthetized with the axillary block (dark blue)

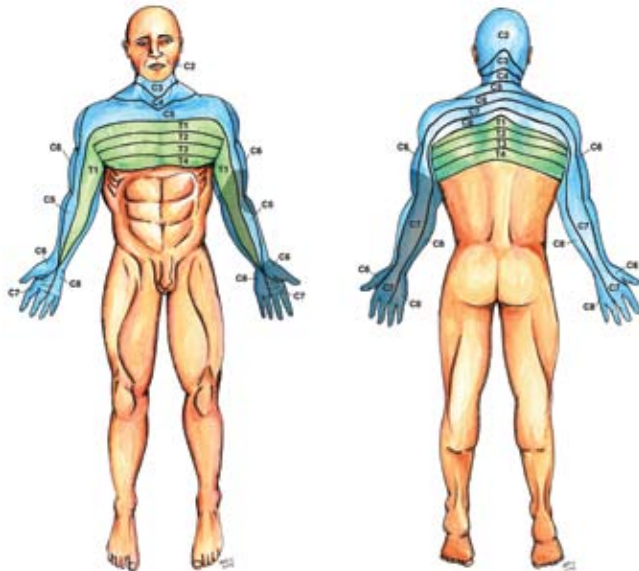
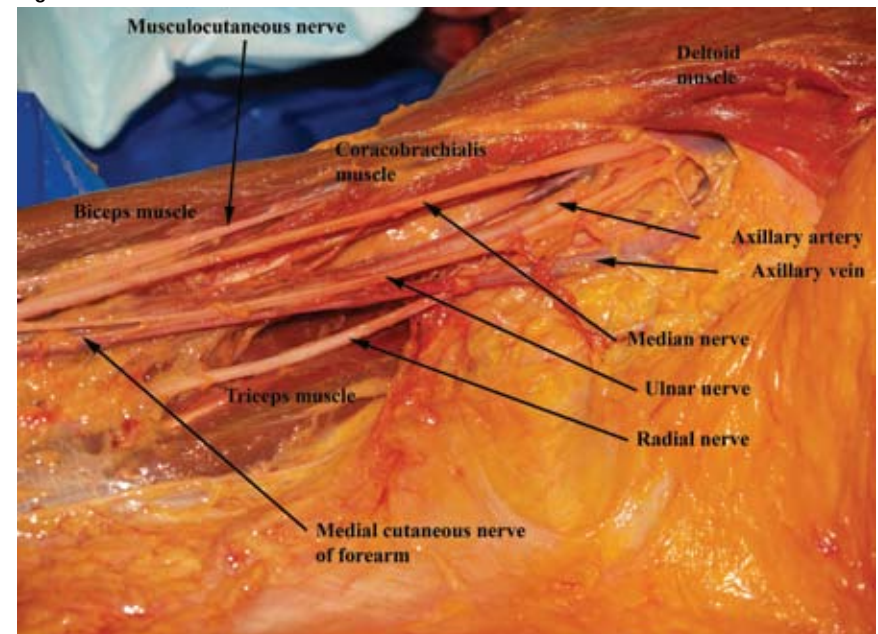


Figure 10-3



## PROCEDURE

**Landmarks.** There are multiple approaches to the axillary block, including paresthesia seeking, nerve stimulating, ultrasound, perivascular, and transarterial techniques. With the paresthesia seeking and nerve stimulating approaches, all four nerves (median, ulnar, radial, and musculocutaneous) can be individually identified and anesthetized; both of these methods seem to be equally successful. However, in procedures using the nerve stimulation technique, studies have shown that actual stimulation of the musculocutaneous nerve leads to a more successful outcome than a simple injection into the coracobrachialis muscle.

It is important to note that although a true axillary sheath may exist, it may not be a tubular structure that neatly houses the terminal branches of the plexus. Instead, it may be a collection of connective tissues that surround the nerves and vessels, creating individual fascial compartments that can inhibit spread of the local anesthetic.

The patient is positioned supine with the operative arm abducted and externally rotated (Figure 10-4). The axillary artery is palpated as high in the axilla as possible. The needle is inserted superior to the axillary artery, entering at a 45° angle. To identify the coracobrachialis muscle for the musculocutaneous block, the biceps muscle is displaced laterally, and the coracobrachialis muscle is palpated just medial to it. At the level of the upper half of the humerus, the needle is inserted into the coracobrachialis muscle.

### Needles

- 22-gauge, 3.8-cm, insulated b-bevel needle.
- 18-gauge, 3.8-cm insulated Tuohy needle for catheter placement. Catheters introduced 3–5 cm.

### Stimulation

**Median, Ulnar, and Radial Nerves.** The nerve stimulator is initially set between 1.0 and 1.2 mA. Finger flexion and/or thumb opposition at 0.5 mA or less indicates proper needle placement (Figure 10-5).

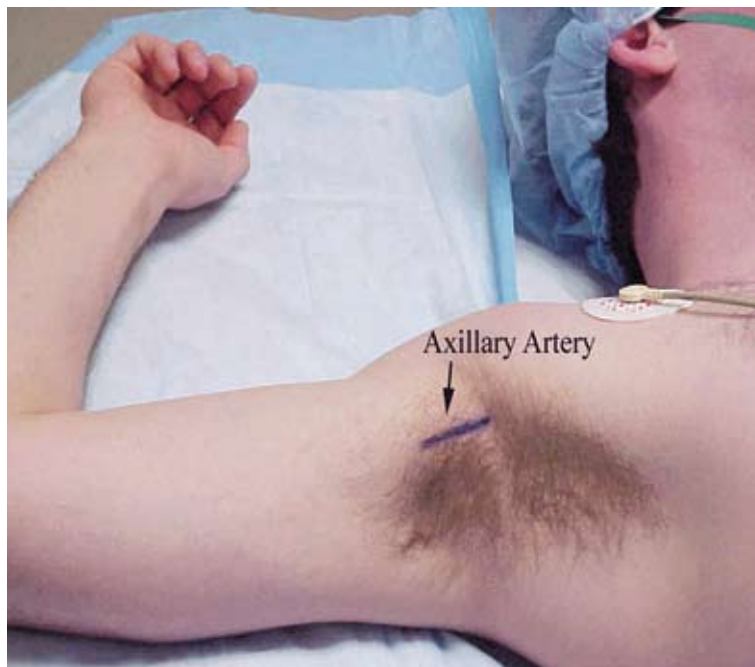

Figure 10-4

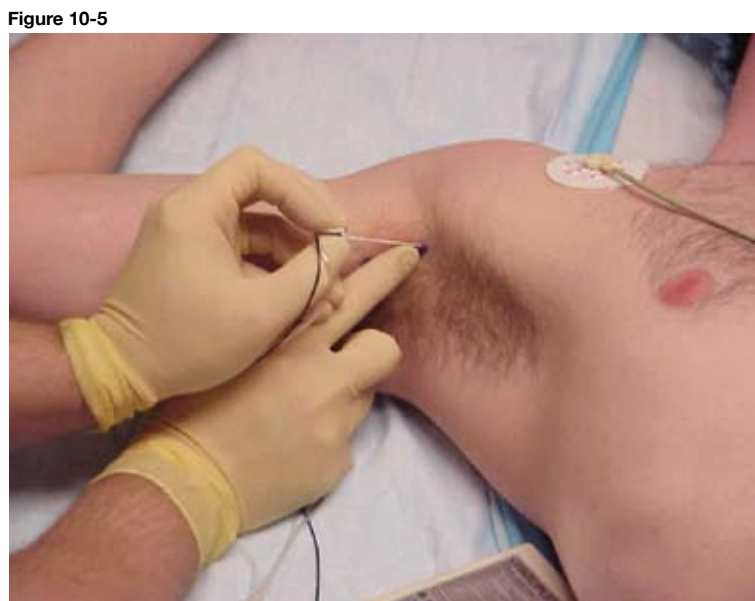

Figure 10-5

Aspiration of bright red blood means the needle has entered the axillary artery. If this occurs, the transarterial technique for axillary block can be used: advance the needle until blood aspiration stops, and deposit half of the local anesthetic volume deep to the artery. Then withdraw the needle until blood aspiration ceases again, and deposit the remaining local anesthetic at this more superficial location.

**Musculocutaneous Nerve.** The nerve stimulator is set to approximately 2.0 mA. Fan the needle through the coracobrachialis muscle until vigorous biceps contraction is elicited (ensure that biceps contraction is not secondary to direct stimulation of the biceps muscle). There is no need to dial down the current.

### Local Anesthetic

**Median, Ulnar, and Radial Nerves.** In most adults, 30 to 40 mL of local anesthetic will block these nerves.

**Musculocutaneous Nerve.** In most adults, 10 mL of local anesthetic will block this nerve.

**Teaching Points.** Application of distal pressure (see Figure 10-5) during injection can help push the local anesthetic in a more proximal direction. Adducting the arm immediately after injection can also help with proximal spread of local anesthetic. If an arm tourniquet is used during the surgical procedure, blockade of the intercostobrachial nerve is required (see Chapter 8, Supraclavicular Block).



## BLOCK WITH ULTRASOUND PROBE

**Probe.** High frequency (5–12 MHz), linear.

**Probe Position.** The transverse plane gives the best view of the brachial plexus at this level; nerves will appear as hypoechoic roundish structures with hyperechoic borders.

**Approach.** The patient is supine, with the arm abducted 90° and externally rotated so the dorsum of the hand rests on the bed. The probe should be placed high in the axilla, at the intersection of the pectoralis major muscle with the biceps muscle (Figure 10-6). At this level, the axillary artery and all three main nerves to be blocked (median, ulnar, radial) should be in view (Figure 10-7). Typical anatomic relations of the nerve to the artery are as follows: the median nerve is located superficial and slightly cephalad to the artery, the radial nerve is located deep to the artery, and the ulnar nerve is located caudad to the artery. If all three nerves are not visualized at the same time, sliding the probe from a medial to lateral direction should help identify the missing nerve. Individual nerves can be confirmed by stimulation. Once each nerve is identified, 10 mL of local anesthetic should be injected around each nerve (Figure 10-8). (Note: axillary veins are often not seen while performing this block under ultrasound guidance because they are easily compressed by the ultrasound probe.)

**Teaching Points.** As opposed to a field block or stimulation technique, blockade of the musculocutaneous nerve under ultrasound guidance is more precise. The patient's arm remains abducted and externally rotated while the probe is positioned at the junction between the pectoralis major and biceps muscles with the axillary artery in view. While the probe

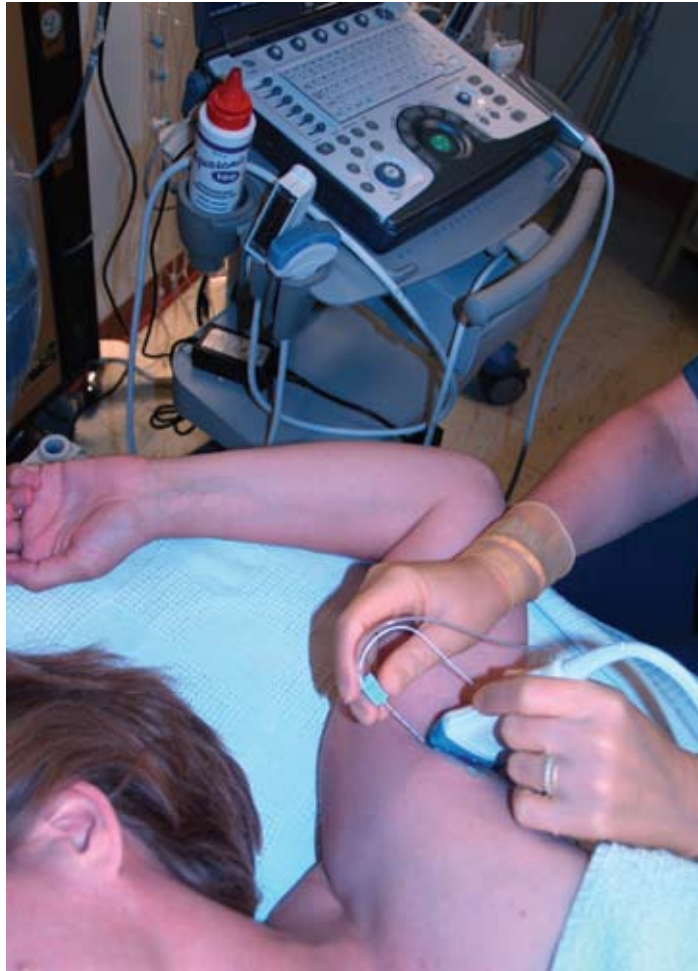

Figure 10-6

is slowly brought toward the biceps muscle, the musculocutaneous nerve should come into view, either between the biceps and coracobrachialis muscles or within the body of the coracobrachialis muscle (Figure 10-9). Local anesthetic should be injected when the needle tip is visualized near the nerve or stimulation of the biceps muscle is noted.

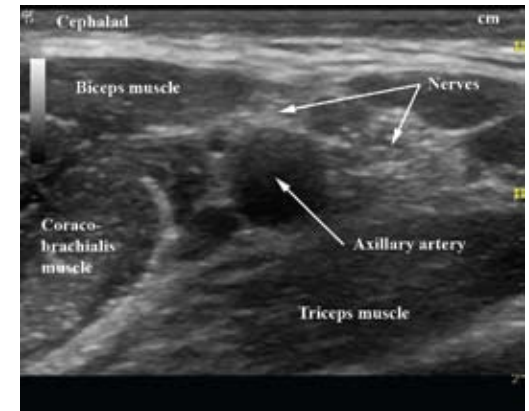


Figure 10-7

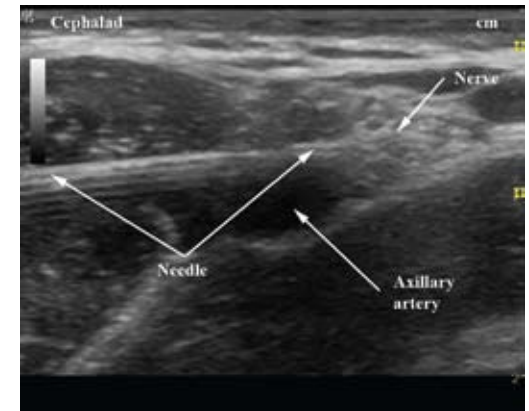


Figure 10-8

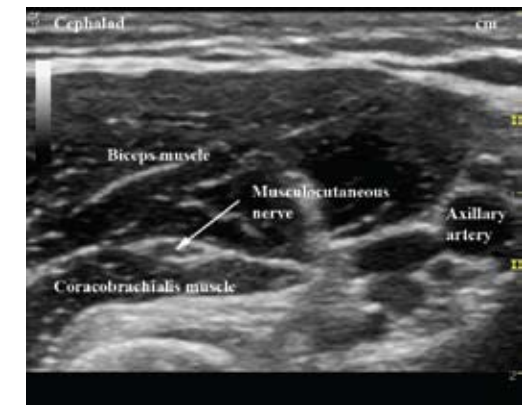

Figure 10-9