

11. PERIPHERAL NERVE BLOCKS OF THE ARM

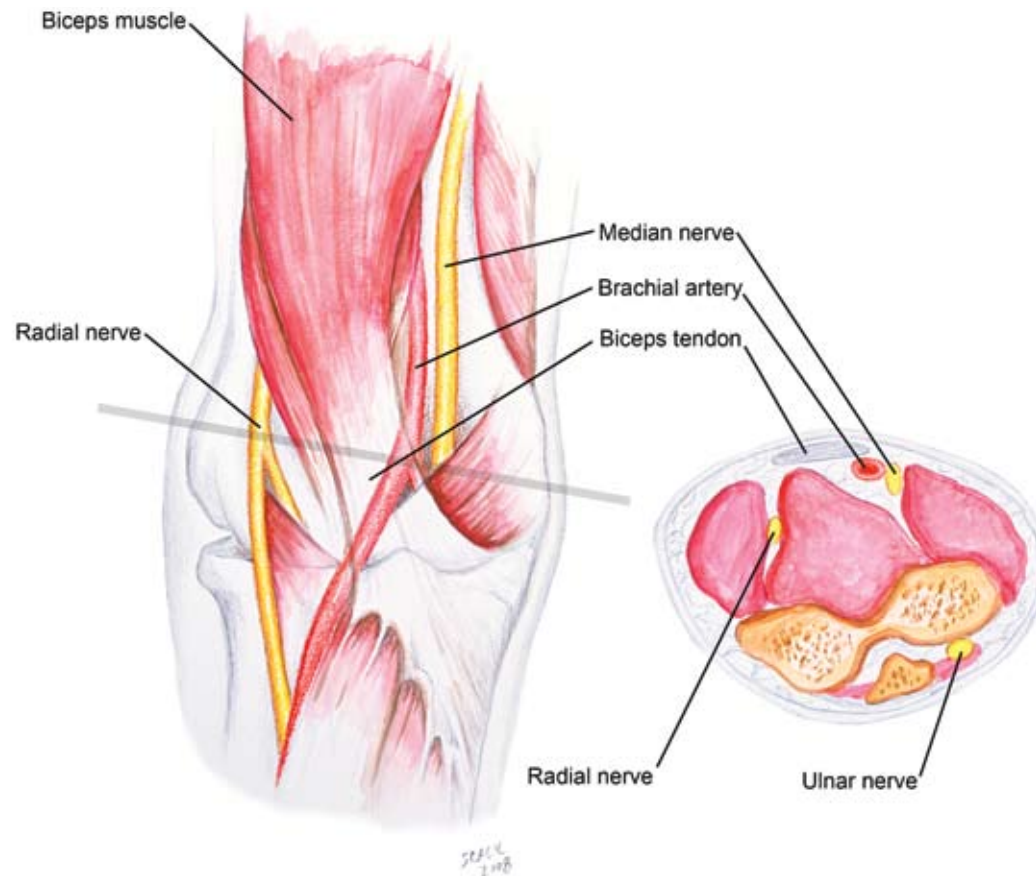
INTRODUCTION

Peripheral nerve blockade of the upper extremity is often accomplished with proximal approaches to the brachial plexus (C5–T1) via supraclavicular, infraclavicular, or axillary nerve blocks. However, a single terminal nerve occasionally requires additional supplementation of local anesthetic to “rescue” a less than adequate block. These distal injection points may also be necessary for a patient with conditions that preclude more proximal injections (eg, preexisting wounds or infection). Coagulation abnormalities may also render the more proximal approaches less desirable because of the close proximity of major vascular structures to the needle entry site. These peripheral techniques are useful for minor surgical procedures within a single nerve distribution, such as wound exploration or small laceration repair.

ANATOMY

The three major peripheral nerves of the upper extremity (radial, median, and ulnar) may all be blocked at the level of the elbow (Figure 11-1). Because of its location within the ulnar groove, the ulnar nerve has the most reliable landmarks. The ulnar groove is palpated between the medial epicondyle of the humerus and the olecranon process. Ulnar nerve blockade at this level provides sensory blockade to the medial aspect of the hand, including the fifth digit and the medial half of the fourth digit.

The brachial artery is the landmark for median nerve blockade at the level of the elbow (see Figure 11-1). The median nerve lies just medial to the artery and may be blocked utilizing paresthesia, nerve stimulation, or ultrasound guidance based on this landmark. Median nerve blockade is useful for the anterolateral surface of the hand, including the thumb through middle finger.



The radial nerve lies between the brachialis and brachioradialis muscles, 1 to 2 cm lateral to the biceps tendon. Using the biceps tendon as a landmark, the radial nerve can be blocked using paresthesia, stimulator, or ultrasound-based techniques. The radial nerve block at this level provides sensory anesthesia to the dorsolateral aspect of the hand (thumb, index, middle, and lateral half of the ring finger) up to the distal interphalangeal joint.

More distal blockade of the upper extremity may be accomplished at the level of the wrist. The median nerve lies between the palmaris longus and flexor carpi radialis tendons. The ulnar nerve is located immediately lateral to the flexor carpi ulnaris and just medial to the ulnar artery. It is important to note that the radial nerve has already branched at the level of the wrist, thus requiring field block over the radial aspect of the wrist.

PROCEDURE

Landmarks. Pertinent landmarks at the level of the elbow consist of the ulnar groove, median and lateral condyles of the humerus, brachial artery pulsation (median nerve), and tendon of the biceps muscle (radial nerve). At the level of the wrist, key landmarks include the tendons of the flexor palmaris longus and flexor carpi radialis (median nerve), anatomic snuffbox (radial nerve), and ulnar styloid (ulnar nerve).

At the Elbow

Radial nerve. Identify the biceps tendon. Insert the needle lateral to the tendon and above the ante-cubital crease (the line bisecting medial and lateral epicondyles). The nerve lies within the groove between the tendon and the brachioradialis muscle (Figure 11-2). Two excellent localization cues are paresthesia and motor response (finger/wrist extension) elicited by a nerve stimulator. Inject 5 to 7 mL of local anesthetic.

Figure 11-2

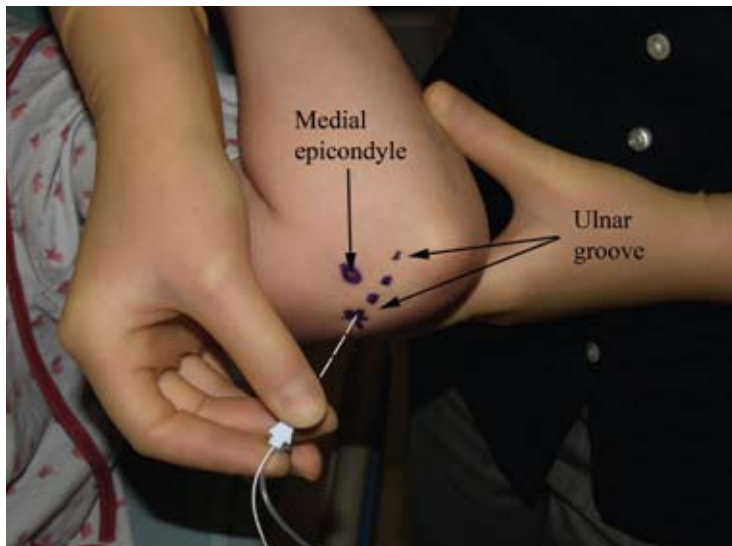
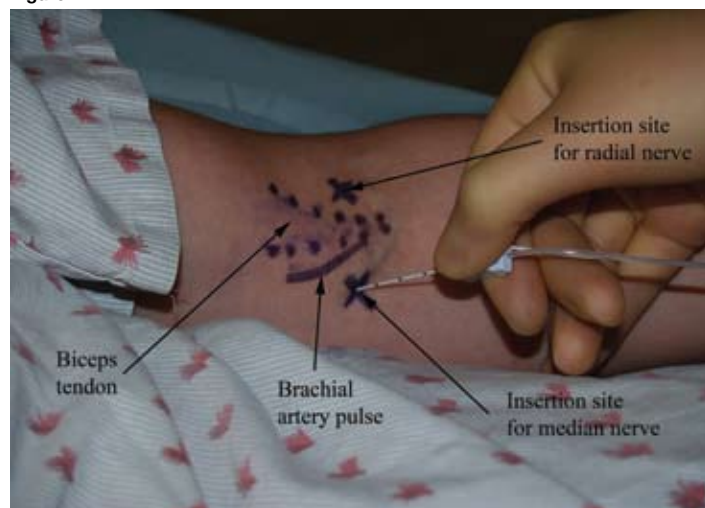


Figure 11-3

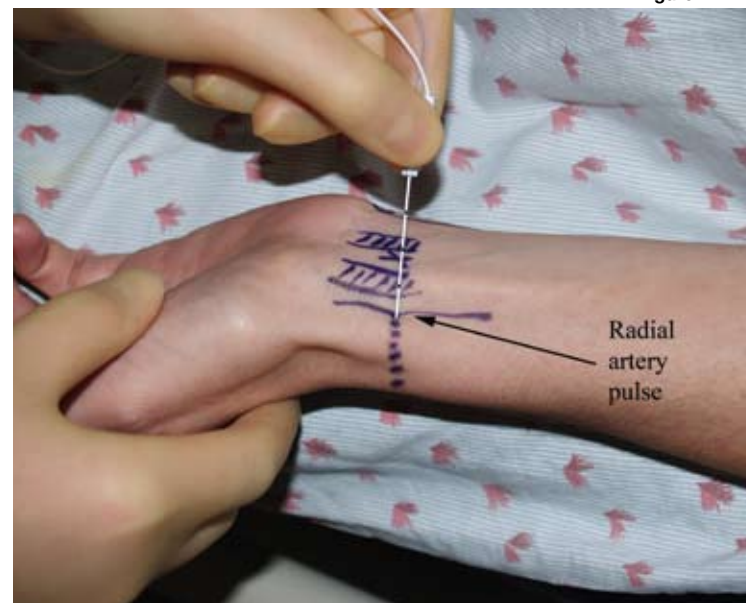
Median nerve. Insert the needle at the antecubital crease, just medial to the palpated brachial pulse (see Figure 11-2). When a paresthesia or motor response (finger/wrist flexion or hand pronation) is elicited, usually at 1- to 2-cm depth, inject 5 to 7 mL of local anesthetic.

Ulnar nerve. With the elbow flexed at mid-range, insert the needle into the ulnar groove 1 to 3 cm proximal to the medial epicondyle. Take care to avoid excessive injection pressure or intraneural injection in this relatively tight space. Limit local anesthetic injection to 4 or 5 mL (Figure 11-3).

At the Wrist

Radial nerve. To block the branches of the radial nerve, make an injection along the radial artery's lateral border 2 cm proximal to the wrist (Figure 11-4). Then extend the injection dorsally over the border of the wrist, covering the anatomic snuffbox. Injection of 5 to 7 mL of local anesthetic is usually sufficient.

Figure 11-4



Median nerve. Identify the tendons of the flexor palmaris longus and flexor carpi radialis by flexing the wrist during palpation. Insert the needle between the tendons 2 cm proximal to the wrist flexor crease, posteriorly towards the deep fascia (Figure 11-5). Inject 3 to 5 mL of local anesthetic while withdrawing the needle.

Ulnar nerve. Many texts describe the ulnar artery pulsation as a landmark for the ulnar nerve block at the wrist; however, the ulnar pulse is difficult to appreciate in many patients. A practical approach is to insert the block needle just proximal to the ulnar styloid process (Figure 11-6). After aspiration to confirm that the needle is not within the ulnar artery, inject 3 to 5 mL of local anesthetic.

Figure 11-5

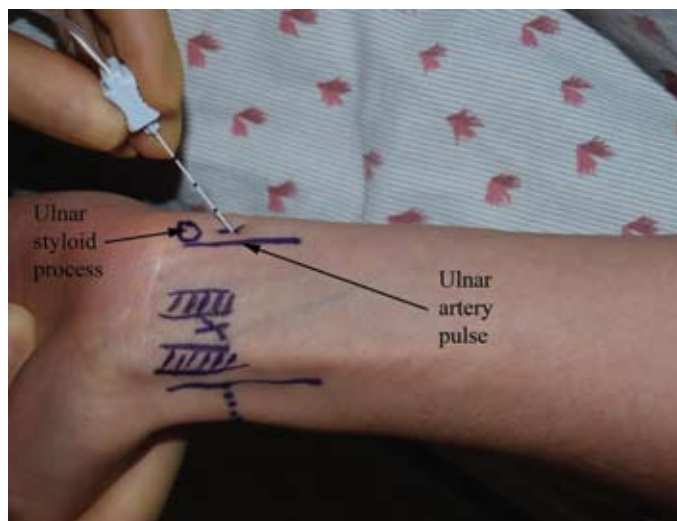
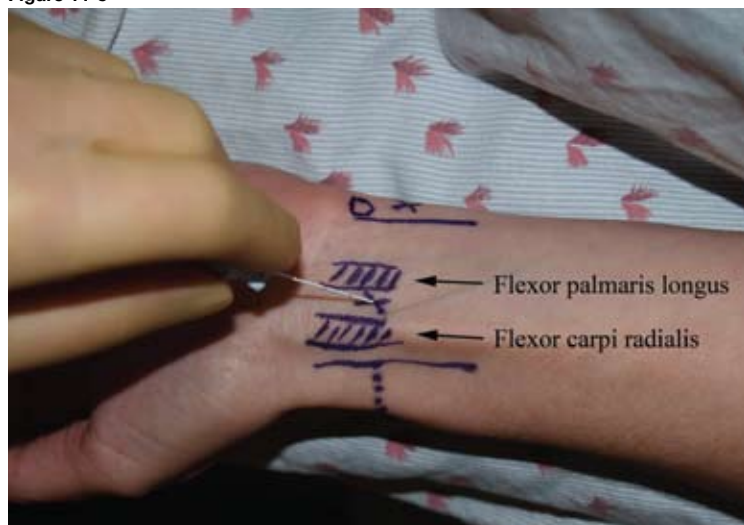


Figure 11-6

Needles

- 22-gauge, 5-cm, insulated needle for nerve stimulation techniques.
- 22-gauge, 5-cm regional needle or 25-gauge, 1- to 1.5-inch b-bevel needle.

Stimulation. Set the nerve stimulator initially at 1.0 to 1.2 mA. Muscle twitches for radial, median, and ulnar distributions should be sought at 0.5 mA or less, indicating adequate proximity to the peripheral nerve prior to injection. Stimulation at the level of the elbow is useful for defining peripheral nerve branches. Peripheral nerve blockade at the wrist is essentially a field block technique, with minimal utility gained from stimulation.

Local Anesthetic. In most adults, 3 to 5 mL of local anesthetic for each desired branch is sufficient. At the level of the elbow, 5 to 7 mL may be used for median and radial nerve blocks. The choice of local anesthetic is determined by user preference; usually mepivacaine, bupivacaine, or ropivacaine is selected. The use of epinephrine 1:400,000 as an adjuvant to local anesthetic is advisable for blocks at the level of the elbow but not recommended for distal blocks such as wrist blocks or digit blocks.

Additional Procedures. When performing an elbow block, an additional 5 mL of subcutaneous local anesthetic injected laterally from the biceps tendon to the brachioradialis muscle will provide anesthesia for the lateral cutaneous nerve of the forearm.

Teaching Points. As with all regional anesthesia techniques, proper injection technique should be followed. This includes frequent aspiration for blood, incremental injection, consideration of injection pressure, and avoidance of “pinning” nerves against underlying bone with the injection needle.

BLOCK WITH ULTRASOUND PROBE

Probe. High-frequency (5–12 MHz), linear.

Approach. Because of the proximity to vascular structures and the smaller size of nerves at this level, the in-plane approach is recommended. Ultrasound views of various nerves at the elbow are presented in Figures 11-7 through 11-9.

Injection. As above, 5 to 7 mL at each injection site.

Figure 11-7. Brachial artery and median nerve of the right arm at elbow level

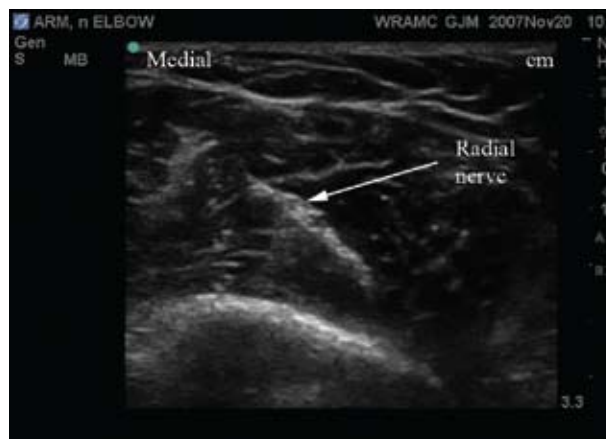
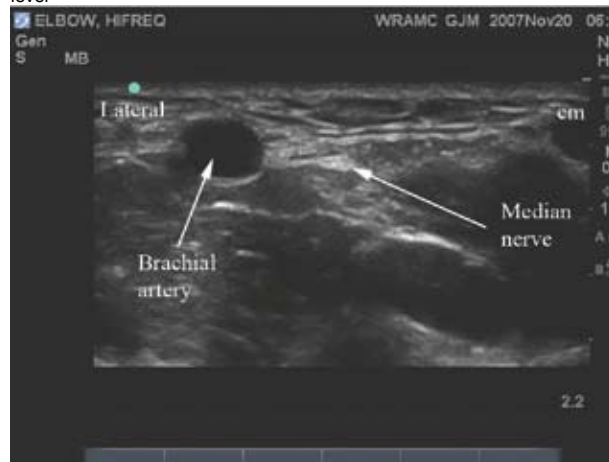
Figure 11-8. Radial nerve of the right arm at elbow level

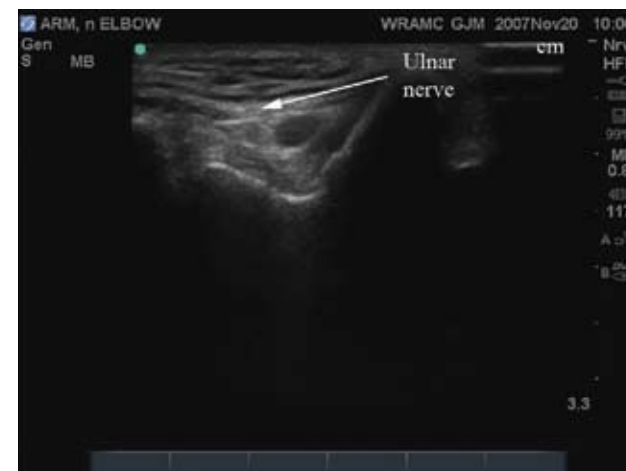

Figure 11-9. Ulnar nerve within the olecranon fossa, right arm

Teaching Points. Use caution when injecting local anesthetic into the olecranon fossa for selective blockade of the ulnar nerve. As shown in Figure 11-9, the ulnar nerve is “trapped” in a confined space at this location. Ensure that injection pressure is not too high, use less than 5 mL of anesthetic, and avoid over-flexing the elbow during the block so the ulnar nerve does not become “pinned” in the fossa and therefore more prone to intraneural injection or damage.

The radial nerve is easily traced from the cubital fossa more proximally to the mid-humeral level. Although the radial nerve may be more superficial proximally, the chance of vascular injury is decreased when the injection is done at the cubital fossa.