

12. PARAVERTEBRAL NERVE BLOCK

INTRODUCTION

Paravertebral nerve blocks (PVBs) have been an established technique for providing analgesia to the chest and abdomen for many years. PVBs are highly versatile and may serve as the primary anesthetic for chest trauma, chest tubes, breast surgery, herniorrhaphy, soft tissue mass excisions, and bone harvesting from the iliac crest, as well as as a useful adjunct in laparoscopic surgery, cholecystectomy, nephrectomy, or other abdominal and thoracic surgeries. In addition, PVBs are a valuable tool in treating acute and chronic pain conditions of the chest and abdomen.

ANATOMY

The paravertebral space is a wedge shaped anatomical compartment adjacent to the vertebral bodies. Its boundaries are defined anterior-laterally by the parietal pleura; posteriorly by the superior costotransverse ligament (thoracic levels); medially by the vertebrae, vertebral disk, and intervertebral foramina; and superiorly and inferiorly by the heads of the ribs (Figure 12-1). The space is further divided into an anterior (ventral) and posterior (dorsal) compartment by the endothoracic fascia. Studies have suggested that to inject as close to the spinal nerves as possible, this fascial layer should be crossed and local anesthetic deposited into the ventral compartment.

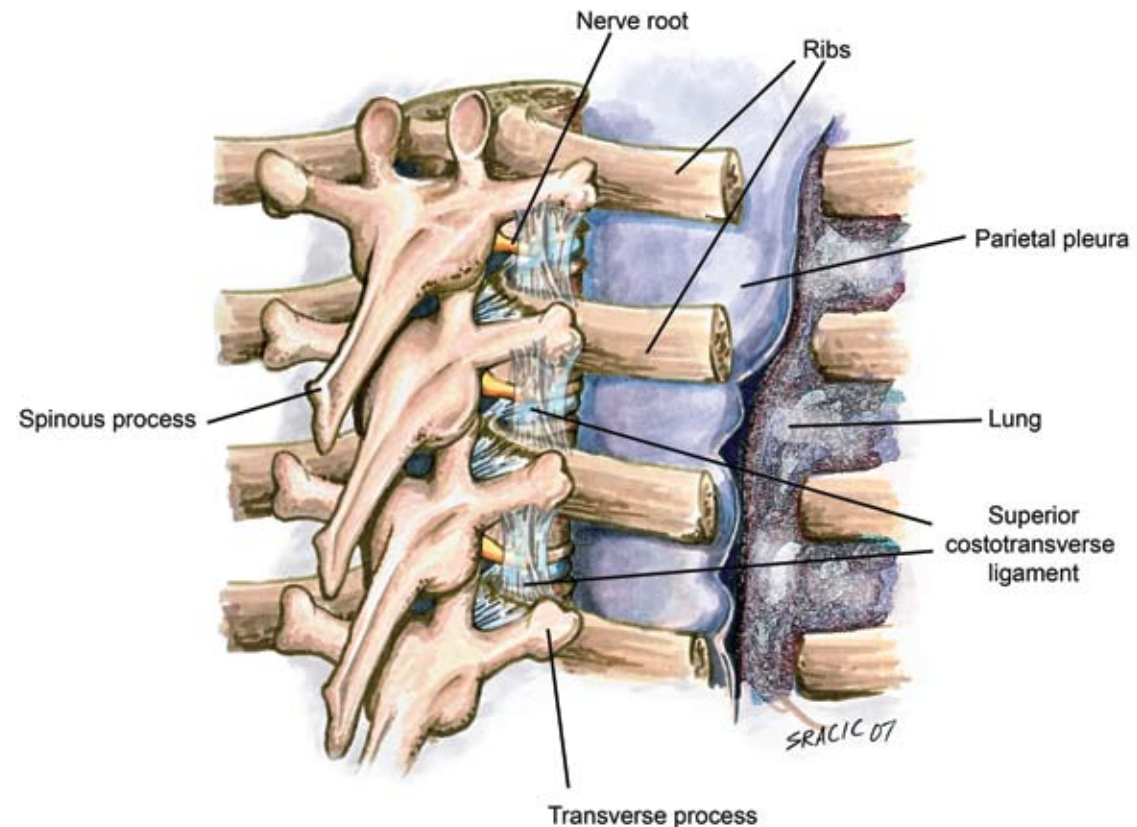
Within the paravertebral space, the spinal nerves are essentially “rootlets” and are not as tightly bundled with investing fascia as they are more distally. This anatomy enhances local anesthetic contact; the nerve roots facilitate dense nerve blockade when a small volume of local anesthetic is introduced into the space. Injection of local anesthetic results in ipsilateral motor, sensory, and sympathetic blockade. Radiographic studies have demonstrated that if the anesthetic is deposited

in the ventral compartment, a multisegmental longitudinal spread typically results, whereas injection into the dorsal compartment will more likely result in a cloud-like spread with limited distribution to paravertebral spaces above and below the injection site. The use of the peripheral nerve stimulator to more accurately place the needle in the ventral compartment can reduce the number of paravertebral injections needed. However, many providers are disinclined to rely on the multisegmental spread of local anesthetic associated with stimulator-guided injections and prefer the multiple injection technique, injecting each individual level required. This places less

emphasis on needle position within the paravertebral space. Both techniques are acceptable.

The median skin-to-paravertebral depth has been demonstrated to be 55.0 mm, with the depth being greater at the upper (T1–T3) and lower (T9–T12) thoracic levels. However, body mass index has been shown to significantly influence the skin-to-paravertebral depth at these levels. Depth is measurable by ultrasound.

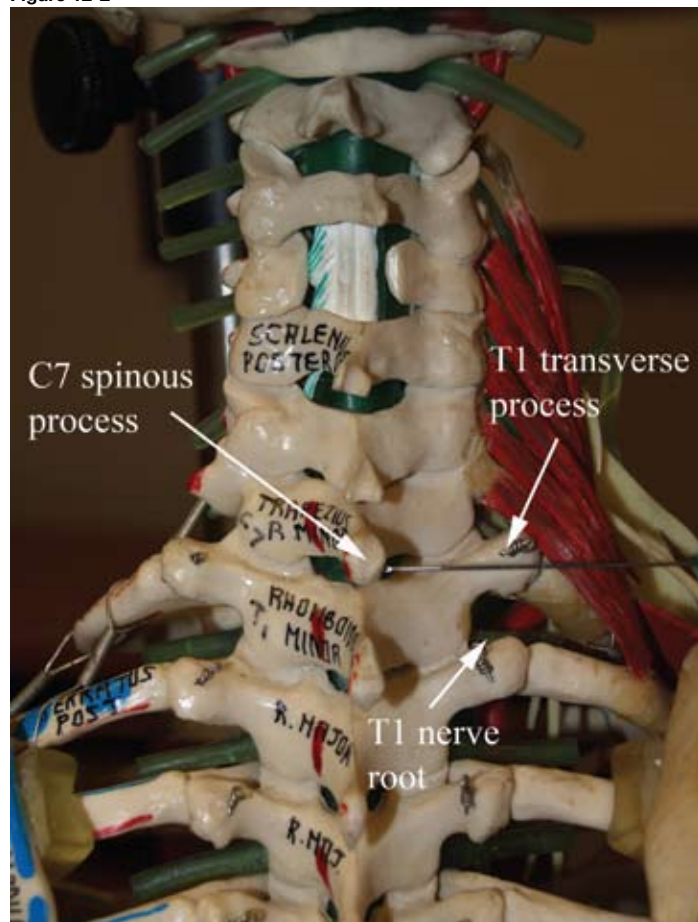
Complications from paravertebral blocks include inadvertent vascular puncture, hypotension, hematoma, epidural spread (via the intervertebral foramina), intrathecal spread (via the dural cuff), pleural puncture, and pneumothorax.



PROCEDURE

Landmarks. The patient is placed sitting upright with the neck and back flexed and the shoulders relaxed forward. The spinous process of each level planned for the block is palpated and marked at its superior aspect. In thoracic paravertebral blocks, the numbered spinous process corresponds to the next numbered nerve root caudally because of

Figure 12-2



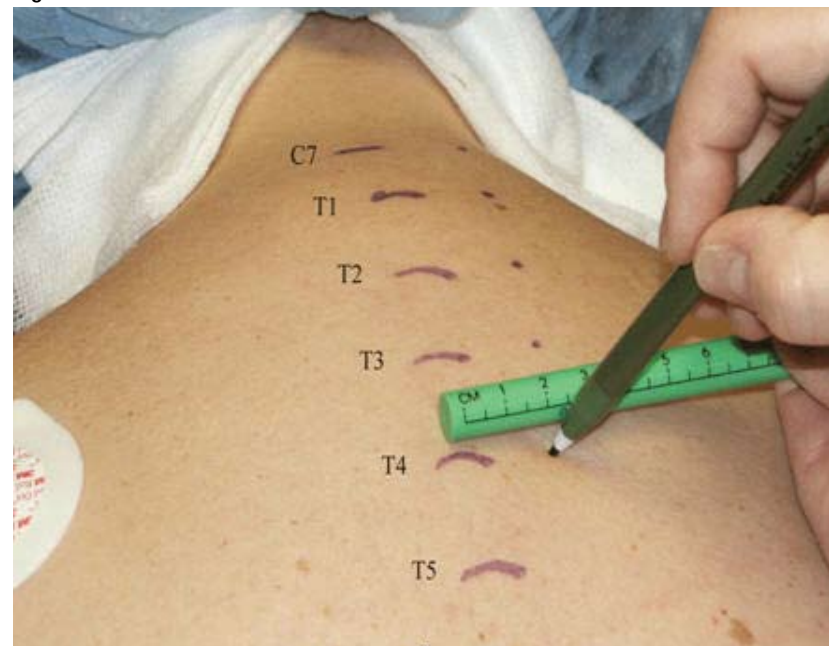the cephalad angulation of the thoracic transverse processes. For example, a paravertebral block performed at the C7 spinous process actually blocks the T1 nerve root if the needle is passed caudally (Figure 12-2). From the midpoint of each spinous process, the needle entry site is marked 2.5 cm laterally (Figure 12-3). In the thoracic area these marks will overlie the transverse process of the next vertebral body, as noted above. In the lumbar area the transverse process is usually at the same level as the spinous process.

For mastectomy surgery with axillary dissection, T1–T6 is routinely blocked. For sentinel node biopsy with possible axillary dissection, blocking T1–T3 is sufficient. For breast biopsy, one injection is made at the dermatome corresponding to the lesion location plus additional injections one dermatome above and below this site. For inguinal herniorrhaphy, levels T11–L2 are blocked. For umbilical hernia, levels T9–T11 are blocked bilaterally. Ventral hernia repair and other applications of PVB require determining the dermatomes involved and then blocking these levels, as well as one dermatome above and below.

Needles

- 21-gauge, 10-cm Tuohy needle with extension tubing.
- 21-gauge, 10-cm insulated needle for stimulation technique.
- 18-gauge, 10-cm Tuohy needle with hemostasis valve/sideport assembly and extension tubing. Catheters placed 2 cm into paravertebral space.

Figure 12-3



Block Without Stimulation. Employing aseptic technique, place a skin wheal of lidocaine local anesthetic at each level to be blocked. The Tuohy needle is attached via extension tubing to a syringe of local anesthetic. Grasp the shaft of the needle in your dominant hand, insert the needle through the skin wheal, and advance it anteriorly in the parasagittal plane (perpendicular to the back) until it contacts the transverse process (2–5 cm deep, depending on the body habitus of the patient). If you cannot identify the transverse process at an appropriate depth, assume that the needle tip lies between adjacent transverse processes, and redirect the needle cephalad and then caudad until the

transverse process is successfully contacted (Figure 12-4). This depth should be noted as the estimated distance to subsequent transverse processes. With the needle contacting the transverse process, grasp the needle shaft with your fingers 1 cm from the skin surface (Figure 12-5). The fingers now serve as a “backstop” to prevent the needle passing beyond 1 cm into the paravertebral space and possibly into the pleura of the lung. Then withdraw the needle tip to the subcutaneous tissue and angle it to “walk off” the caudad edge of the transverse process, advancing no more than 1 cm into the space. Often, a loss of resistance or “pop”

is appreciated, indicating that the needle tip has penetrated the superior costotransverse ligament. After gentle aspiration of the syringe for blood and air, inject 3 to 5 mL of local anesthetic into the space.

Resistance to local anesthetic injection indicates that the needle tip is not in the paravertebral space or has not penetrated the ligament. If this occurs, advance the needle no more than 0.5 cm

until the resistance lessens (the tip has passed beyond the ligament) or bone is contacted (necessitating repositioning of the needle). The reason for the caudal direction of needle placement is that if initial bone contact is inadvertently with the rib (too deep to the paravertebral space), “walking off” caudally will lead to needle contact with the transverse process at a more superficial point (“stepping up”), thus minimizing unintended deep needle insertion (Figure 12-6).

Figure 12-4. Finding the transverse process

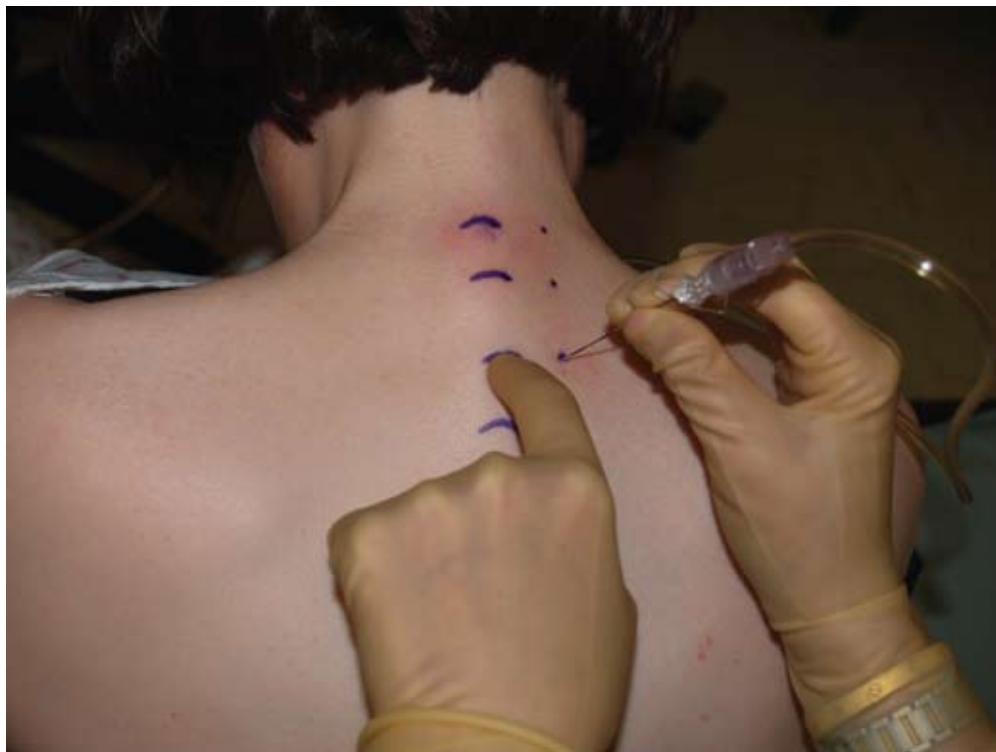

Figure 12-5. Finger backstop

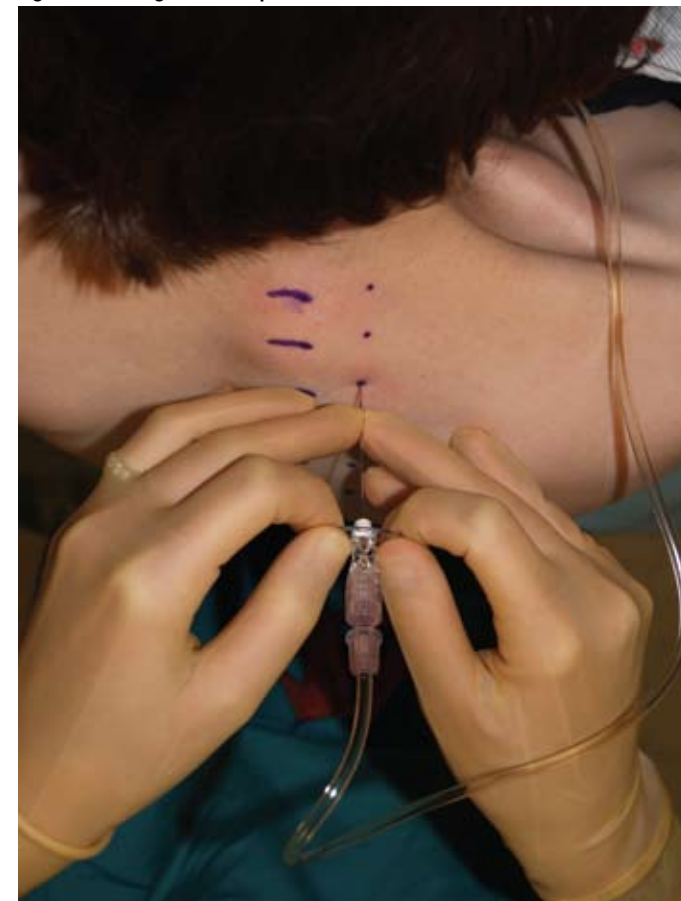
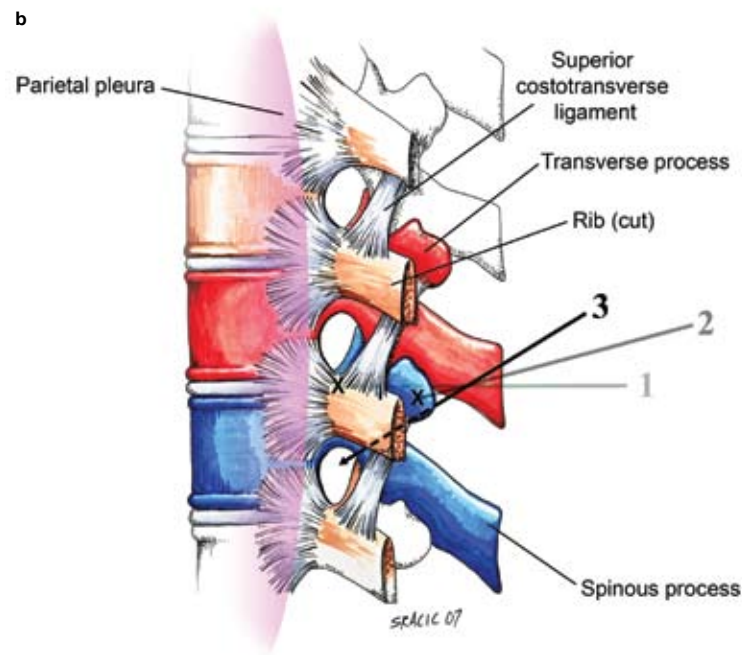
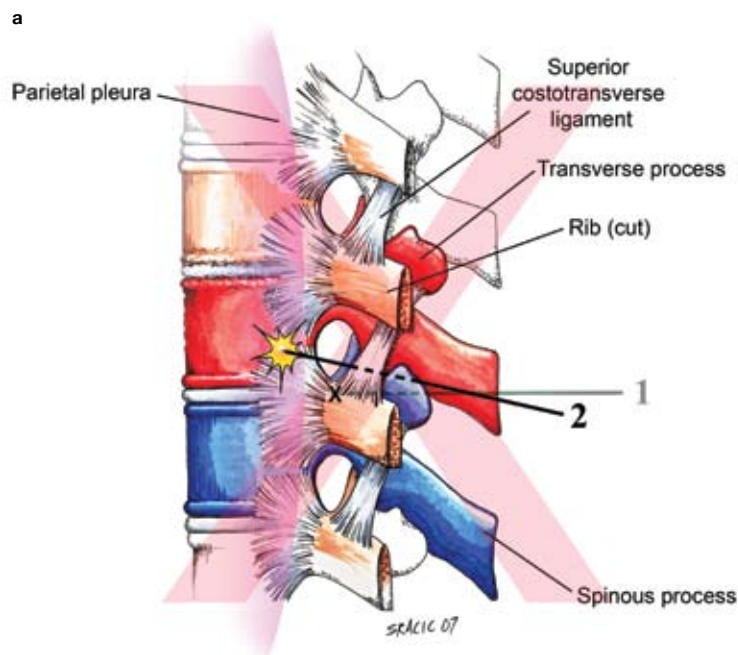


Figure 12-6. Cephalad versus caudal needle redirection for thoracic paravertebral blocks with erroneous initial needle contact with the rib. (a) In this figure the needle inadvertently contacts the rib (a-1), rather than the desired transverse process. If the provider directs the needle cephalad as depicted (a-2), inadvertent needle penetration of the pleura is possible. Therefore, cephalad needle redirection is NOT recommended. (b) In this figure the needle again incorrectly contacts the rib (b-1); however, with caudal redirection (recommended), this error is detected when the needle “steps up” onto the transverse process (b-2). With correct contact of the needle with the transverse process, the needle can be directed caudad into the paravertebral space with confidence using the 1-cm finger “backstop” (b-3).



Block With Stimulation. After identifying landmarks and prepping the area, attach a 21-gauge insulated needle to a nerve stimulator and turn the current to 2.5 mA. Advance the needle through the skin, perpendicular in all planes. Occasionally, contractions of the paraspinal muscles are seen at this point. Place the needle into the paravertebral space as described above for nonstimulating paravertebral blocks. Once the needle has advanced through the superior costotransverse ligament, any paraspinal contractions will stop and an intercostal muscle twitch will typically be observed. The patient can often confirm the contraction of his or her chest wall. Gently manipulate the needle tip to continue to view this twitch as you decrease the stimulator current to approximately 0.8 mA. The needle tip should now be within the ventral com-

partment of the paravertebral space and beyond the endothoracic fascia. Inject local anesthetic as above. The stimulation technique provides a more objective indication of correct needle placement within the space.

Local Anesthetic. For multiple injection techniques, 3 to 5 mL of local anesthetic (usually 0.5% ropivacaine) is injected at each space. Smaller volumes are injected when bilateral paravertebral blocks (more than 6 injections) are required. Larger volumes of 10 to 15 mL can be injected at a single thoracic level with typical spread of the local anesthetic 1 to 2 paravertebral levels above and below the injection level, particularly when stimulation is used. Each syringe of local anesthetic should contain epinephrine 1:400,000 as a marker of intravascular injection.

Teaching Points. At the thoracic levels it is common to appreciate a loss of resistance or a subtle “pop” as the needle passes through the superior costotransverse ligament. In the lumbar region, there is no superior costotransverse ligament. If a distinct “pop” is sensed here, the needle has likely punctured the psoas fascia and should be withdrawn to a more shallow depth, still remaining anterior to the transverse process.

In addition, it is important to note that in the lumbar region, the transverse process is very thin, so the needle should be inserted only 0.5 cm past the transverse process. If using the nerve stimulator technique for thoracic paravertebral blocks, be aware that a blunt-tip Tuohy needle is not being used, which may increase the risk of pleural puncture.