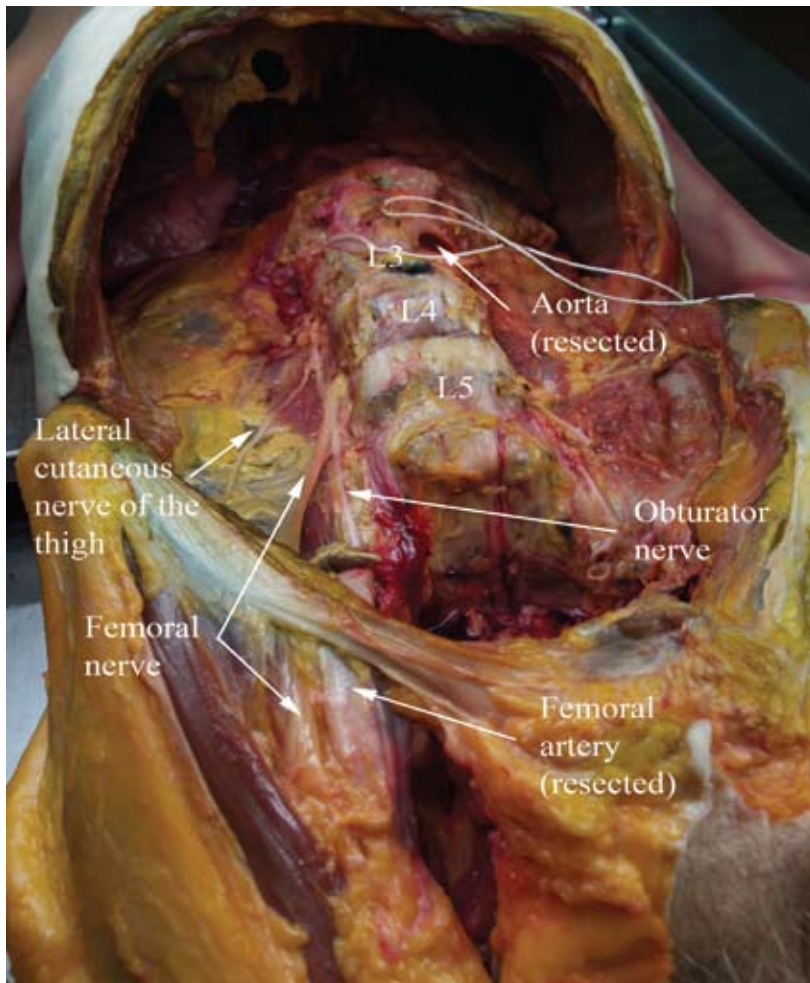


13. LOWER EXTREMITY NEUROANATOMY

INTRODUCTION

Regional anesthesia of the lower extremity involves two major nerve plexuses, the lumbar plexus and the sacral plexus. The safe practice of lower extremity regional anesthesia depends on a comprehensive understanding of neuroanatomy in this region of the body.

Figure 13-1. Dissected right lumbar plexus. The exposed nerves have been dissected from the substance of the psoas muscle, which has been removed.

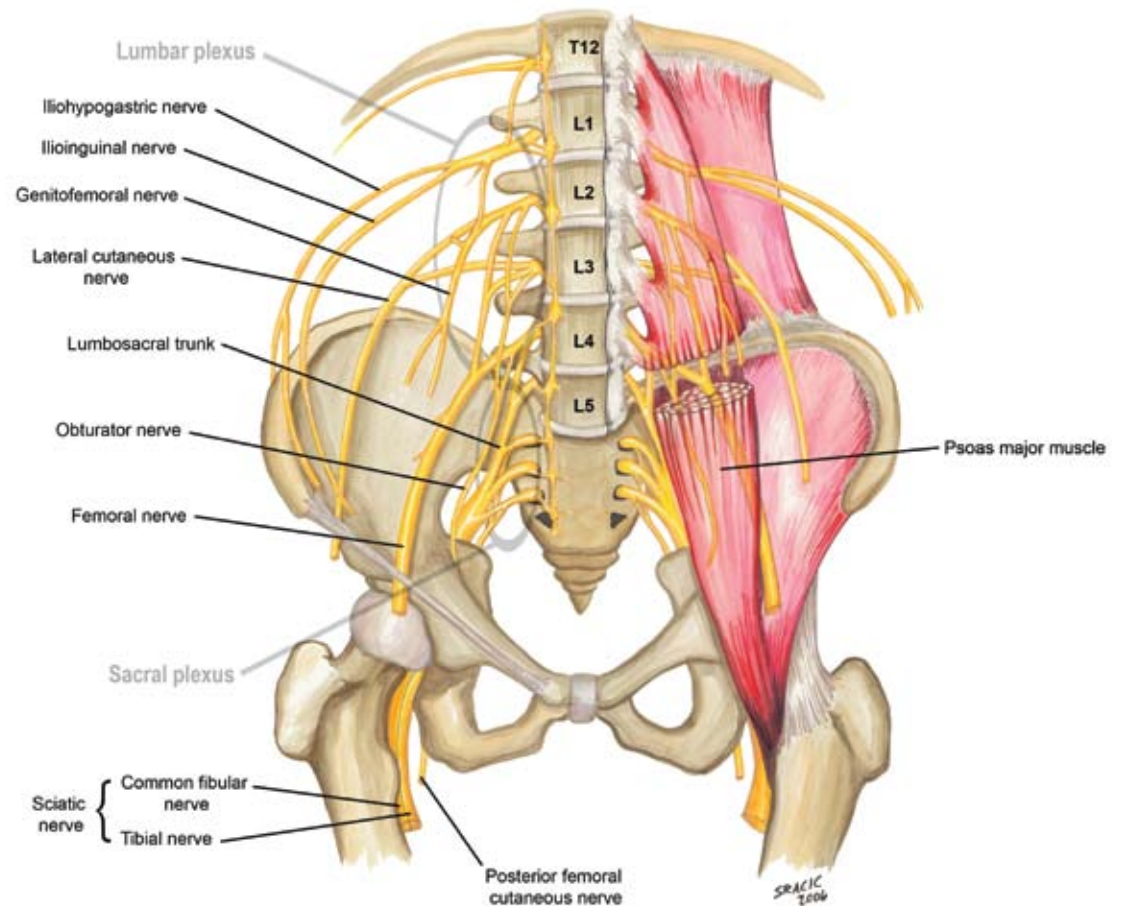


LUMBAR PLEXUS

The lumbar spinal nerves exit caudad to their numbered vertebrae and divide into posterior and anterior rami. The posterior rami of L1 through L5 supply the muscles and skin of the back. The lumbar plexus (Figure 13-1) consists of the anterior rami of L1 through L4. It forms anterior to the lumbar transverse processes within the proximal body of the psoas muscle. The major nerves of the lumbar plexus include the following (Figure 13-2):

- *Ilioinguinal and iliohypogastric nerves (L1)*: passes anterior to the quadratus lumborum and emerges near the anterior superior iliac spine to innervate the abdominal muscles and skin of the inguinal and pubic area.
- *Lateral femoral cutaneous nerve (L2, L3)*: emerges medial to the anterior superior iliac spine, passing deep to the inguinal ligament, to supply sensation to the anterolateral surface of the thigh.

Figure 13-2. Lumbar plexus and sacral plexus



- *Femoral nerve* (L2–L4): passes deep to the inguinal ligament to innervate the iliacus, hip flexors, and knee extensors of the thigh.
- *Obturator nerve* (L2–L4): passes medial to the psoas muscle, into the pelvis, and through the obturator foramen to innervate the medial thigh (adductors).
- *Lumbosacral trunk* (L4, L5): passes over the sacrum into the pelvis and joins the formation of the sacral plexus from the anterior rami of S1 through S4.

SACRAL PLEXUS

The sacral plexus is found within the lesser pelvis on the anterior surface of the piriformis muscle. It is formed from the anterior spinal nerve rami of L4 through S4. Most of the nerves originating from the sacral plexus leave the pelvis via the greater sciatic foramen. The major nerves of the sacral plexus are the following (see Figure 13-2):

- *Sciatic nerve* (L4–S3): travels in the posterior thigh to provide motor and sensory innervation to the posterior thigh and majority of the lower leg (with the exception of the medial lower leg). The largest nerve in the body, the sciatic nerve is composed of two individual nerves, the tibial nerve and common peroneal nerve, traveling together within the same nerve sheath (Figure 13-3).
- *Pudendal nerve* (S2–S4): enters the perineum via the lesser sciatic foramen. The pudendal nerve is the primary nerve of the perineum providing sensation to the genitalia and motor innervation to the muscles of the perineum.
- *Posterior femoral cutaneous nerve* (S2–S3): provides

cutaneous innervation of the buttock and proximal medial/posterior surfaces of the thigh (see Figure 13-3).

- *Superior gluteal nerve* (L4–S1): leaves the pelvis superior to the piriformis and innervates the

gluteal muscles (gluteus medius and gluteus minimus) and the tensor to the fascia lata.

- *Inferior gluteal nerve* (L5–S2): leaves the pelvis inferior to the piriformis and superficial to the sciatic nerve, branching to innervate the gluteus maximus muscle.

Figure 13-3. Sciatic nerve within fascial sheath dissected at posterior mid-thigh

