

14. LUMBAR PLEXUS BLOCK

INTRODUCTION

The lumbar plexus consists of a group of six nerves that supply the lower abdomen and upper leg. Combined with a sciatic nerve block, the lumbar plexus block can provide complete analgesia to the lower extremity. This procedure is an alternative to neuraxial anesthesia, which also anesthetizes the nonoperative leg and occasionally results in urinary retention. The complete lumbar plexus can be blocked from a posterior approach (also known as the psoas compartment block), although the individual nerves of the plexus can be accessed anteriorly as well.

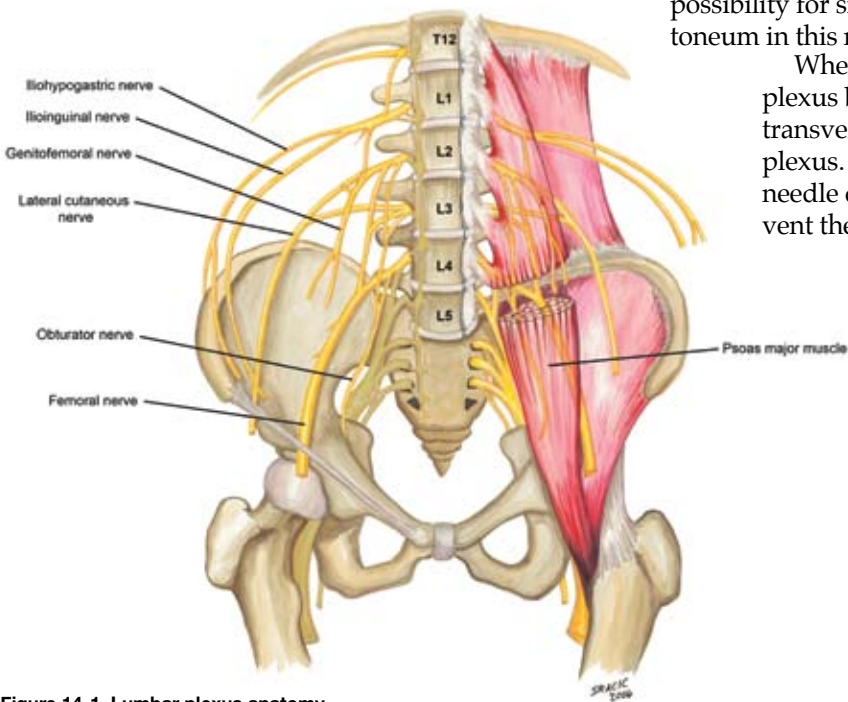


Figure 14-1. Lumbar plexus anatomy

ANATOMY

The lumbar plexus is formed from the ventral rami of L1–L4 with variable contributions from T12 and L5 (Figure 14-1). The peripheral branches of the lumbar plexus include the iliohypogastric, ilioinguinal, genitofemoral, lateral femoral cutaneous, femoral, and obturator nerves. The plexus forms within the body of the psoas muscle (Figure 14-2), and the lumbar plexus block consistently blocks the three nerves that supply the lower extremity (femoral, lateral femoral cutaneous, and obturator—Figure 14-3). As it passes to the pelvis, the obturator has more variability of location and is separated from the other two nerves of the plexus by the psoas muscle. This is why the femoral nerve block (also called the “3-in-1 block”) often fails to successfully block the obturator nerve and why the lumbar plexus approach is often selected when blockade of all three nerves is required. However, the lumbar plexus block remains controversial because of the deep location of the plexus within the psoas muscle and the possibility for significant bleeding into the retroperitoneum in this noncompressible area of the body.

When performing a posterior lumbar plexus block, it is important to contact the L4 transverse process before entering into the plexus. This bony landmark will serve as a needle depth safety point that should prevent the operator from advancing too deep into the retroperitoneum. Studies have shown that although variability exists in distances from the skin to the L4 transverse process among men and women with varying body mass indexes, once the transverse process is reached, the distance to the lumbar plexus is no more than 20 mm.

Complications from a posterior lumbar plexus block include intrathecal injection, epidural injection or diffusion (the most common complication), intravascular injection, and retroperitoneal bleeding.

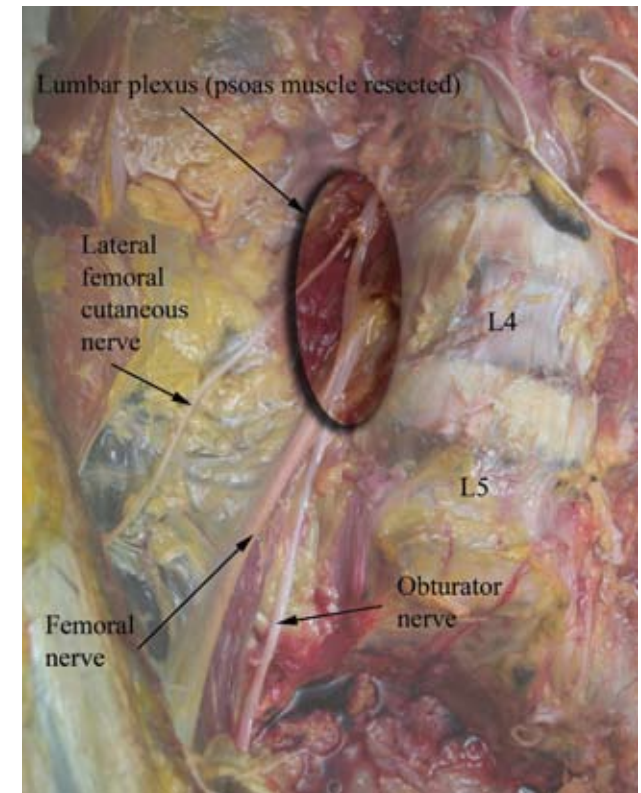


Figure 14-2. Lumbar plexus dissection

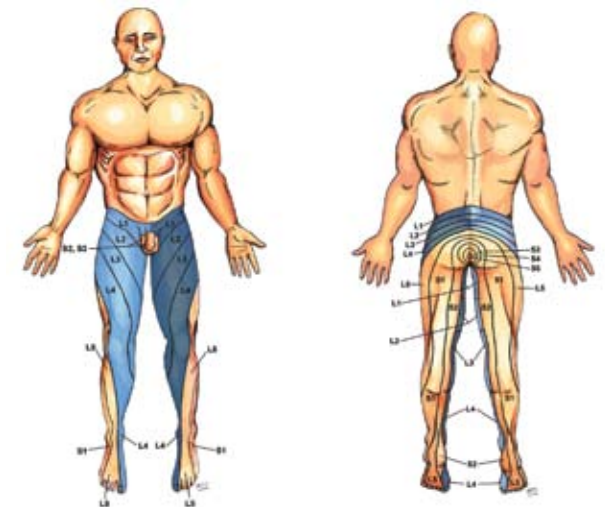


Figure 14-3. Dermatomes anesthetized with the lumbar plexus block (dark blue)

PROCEDURE

Landmarks. The patient is placed in the lateral decubitus position with the operative side up. A line is drawn from the top of the posterior iliac crest down to midline. Known as the “intercrystal line,” this line is positioned over the L4 transverse process in most adults. The intersection of the intercrystal line with a line drawn parallel to the spine from the posterior superior iliac spine determines the initial needle insertion point and is 5 cm lateral from midline in most patients (Figure 14-4).

Needles

- 21-gauge, 10-cm insulated needle for the majority of patients. 15-cm needles may be needed for obese patients.
- 18-gauge, 10-cm insulated Tuohy needle for catheter placement. Catheters introduced 5 cm beyond needle tip.

Stimulation. Set the nerve stimulator initially at 1.0 to 1.2 mA, and look for a quadriceps muscle twitch (femoral nerve) as evidence of needle proximity to the lumbar plexus (this twitch is usually encountered at a depth of 5 to 8 cm from the skin). Insert the needle with a slight medial angulation to the sagittal plane of the patient (Figure 14-5). Make small adjustments of the needle tip caudad and cephalad if initial passes fail to contact os. Once bone is contacted (usually the transverse process of L4), bring the needle back towards the skin, redirecting it caudally to “walk off” the process. The plexus should be stimulated at a depth of no more than 2 cm beyond the transverse process; beyond this the risk of injury to retroperitoneal structures is increased. Decrease the stimulator current to 0.5 mA. If the twitch remains evident with the decreased current, injection of local anesthetic can proceed.

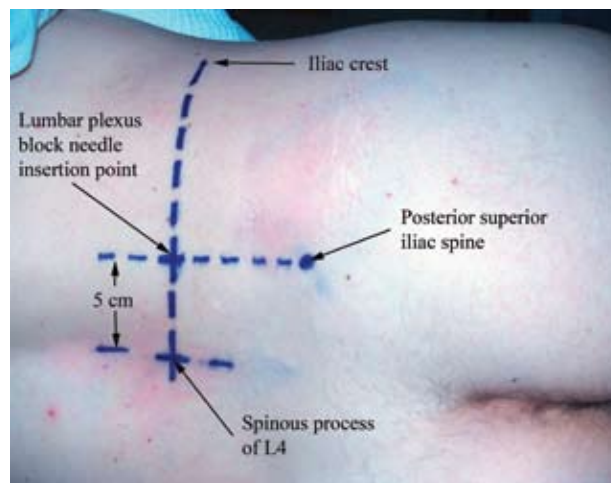


Figure 14-4. Lumbar plexus block landmarks

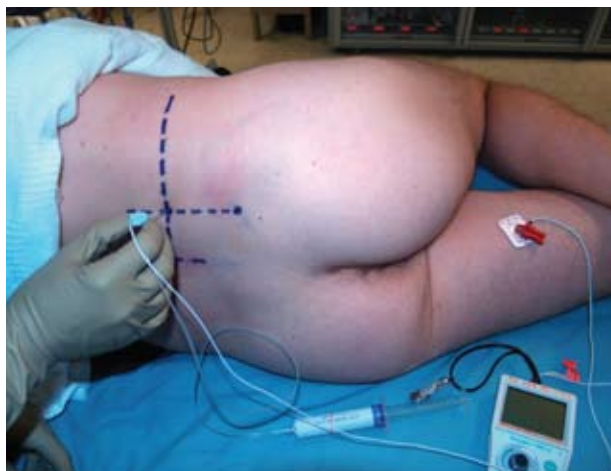


Figure 14-5.

Ultrasound can be used to confirm bony anatomical landmarks for this block (along the L4 transverse process); however, the depth of the plexus in adults will make visualization of the nerves difficult.

Local Anesthetic. In most adults, 30 to 40 mL of local anesthetic is sufficient to block the plexus.

Teaching Points. Occasionally stimulation of the hamstring muscles of the posterior thigh will be noted while attempting to perform the lumbar plexus block. This suggests sacral plexus stimulation (sciatic nerve) and indicates the needle tip is too caudal and medial. Injection here may lead to epidural spread or incomplete block of the plexus. Adjustment of the initial needle insertion point 1 cm cephalad and 1 cm lateral compensates for this error.

If os is repeatedly encountered despite “walking off” the transverse process, the needle tip may be too medial and may be hitting the vertebral lamina. Pull the needle back towards skin and redirect slightly more lateral.

The term “os” is specifically used rather than “bone” to remind the physician that lightly sedated patients may become concerned or agitated if they hear the needle described as contacting their bone. The term “os” is less familiar and therefore less alarming to patients, and this term should be used while discussing bony landmarks during regional anesthetic procedures.