

## 16. INDIVIDUAL NERVE BLOCKS OF THE LUMBAR PLEXUS

### LATERAL FEMORAL CUTANEOUS NERVE BLOCK

**Introduction.** The lateral femoral cutaneous (LFC) nerve is a purely sensory nerve derived from the L2–L3 nerve roots. It supplies sensory innervation to the lateral aspect of the thigh (Figure 16-1). Because it is one of six nerves that comprise the lumbar plexus, the LFC can be blocked as part of the lumbar plexus block. Most of the time, but not always, it can also be simultaneously anesthetized via a femoral nerve block. An occasional need arises to perform an individual LFC nerve block for surgery such as a thigh skin graft harvest or for the diagnosis of myalgia paresthetica (a neuralgia of the LFC nerve).

**Anatomy.** The LFC nerve emerges from the lumbar plexus, travels along the lateral aspect of the psoas muscle, and then crosses diagonally over the iliacus muscle. After traversing beneath the inguinal ligament, it enters the thigh and passes medially to the anterior superior iliac spine (ASIS). It is the rela-

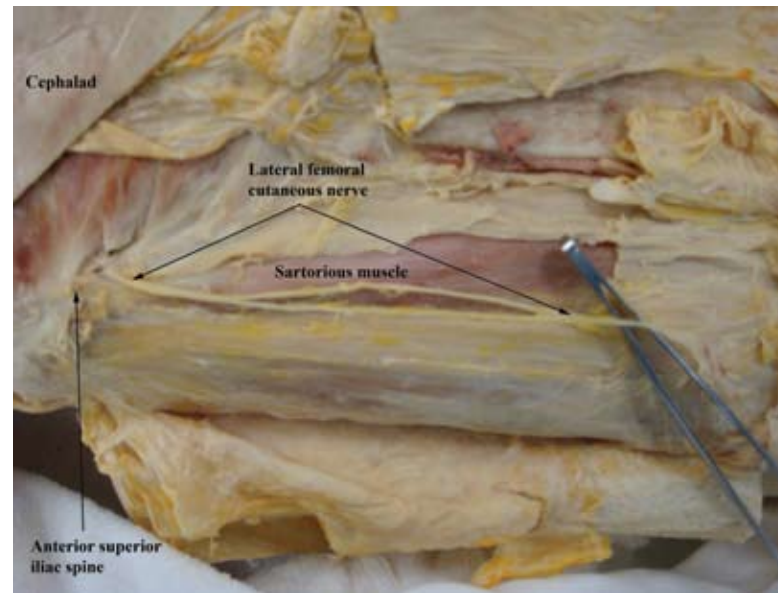


Figure 16-2

tionship of the nerve to the ASIS that anatomically defines this block (Figure 16-2).

**Procedure.** Because the LFC nerve is purely sensory, nerve stimulation is not typically used. Insert the needle perpendicular to all planes at a point 2 cm caudal and 2 cm medial to the ASIS. Advance the needle until a loss-of-resistance is felt; this signifies the penetration of the fascia lata. Inject 5 mL of local anesthetic at this location, then redirect the needle first medially and then laterally, injecting an additional 5 mL at each of these points (Figure 16-3).

**Teaching Point.** A useful procedure in both the pediatric and adult populations is a variation of the LFC nerve block, the fascia iliaca block. Like the femoral “3-in-1” block, the fascia iliaca block often fails to anesthetize the obturator nerve. To perform this procedure, draw a line from the ASIS to the pubic tubercle, and divide it into thirds. At the point where the lateral and middle thirds meet, draw a line 1 cm caudally, and insert the needle at this point. Two fascial “pops” will be felt, in-

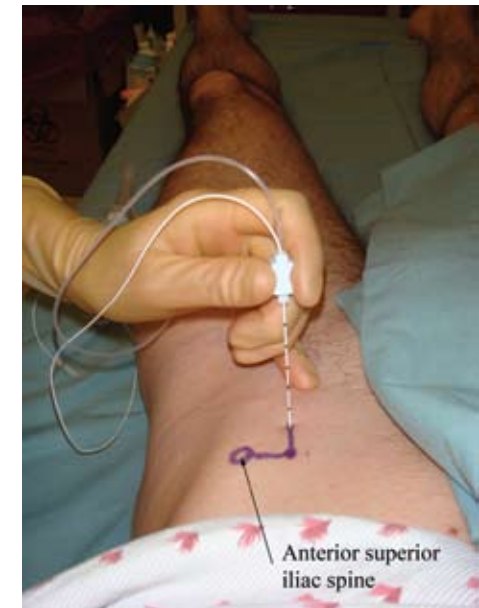


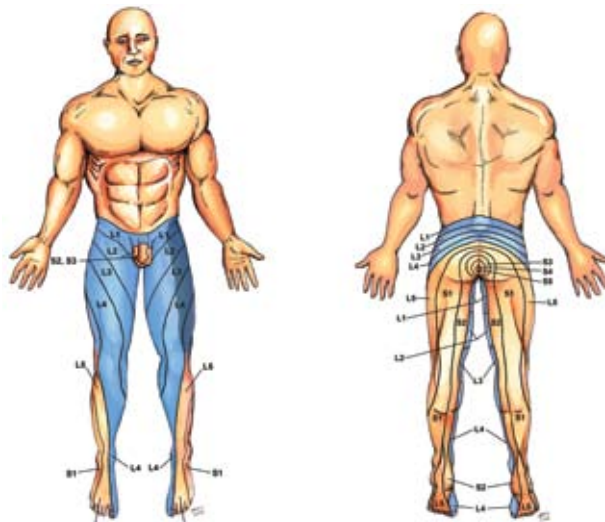
Figure 16-3

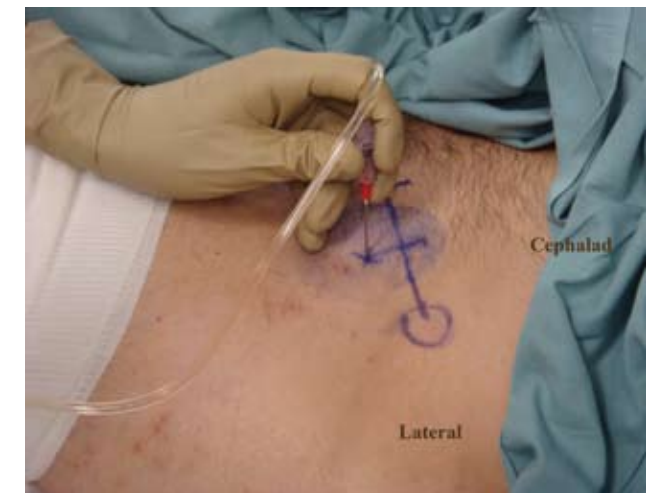

Figure 16-4

dicating the fascia lata and the fascia iliaca. After the second pop, drop the needle to a 30° angle, and advance it 1 cm. Slowly inject 30 mL of local anesthetic (Figure 16-4).

Figure 16-1. Dermatomes anesthetized with the LFC block (dark blue)

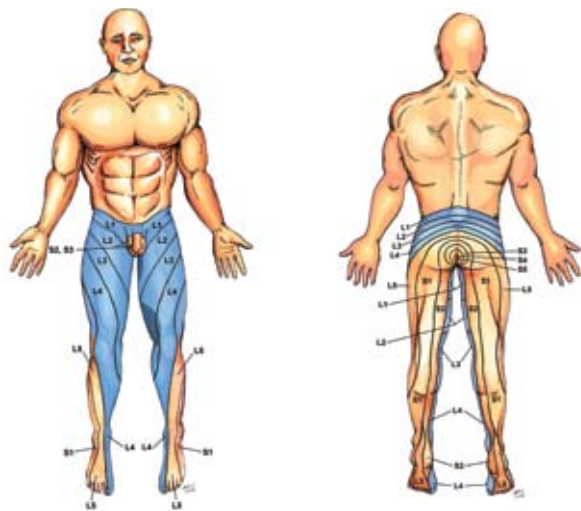


## OBTURATOR NERVE BLOCK

**Introduction.** The obturator nerve is a mixed sensory and motor (mainly motor) nerve originating from the L2 through L4 anterior rami. It supplies sensory innervation to the medial aspect of the thigh (Figure 16-5) and motor innervation to the medial thigh muscles responsible for adduction of the leg (adductors longus, brevis, and magnus; gracilis and obturator externus muscles). In rare occasions an isolated obturator nerve block is performed; more often, the nerve may need to be blocked in conjunction with other anterior approaches to the lumbar plexus nerves, such as a femoral nerve block.

**Anatomy.** The obturator nerve travels as a single nerve from the lumbar region down toward the pelvis within the body of the psoas muscle. It crosses the pelvis vertically, exiting via the obturator foramen (immediately below the superior pubic

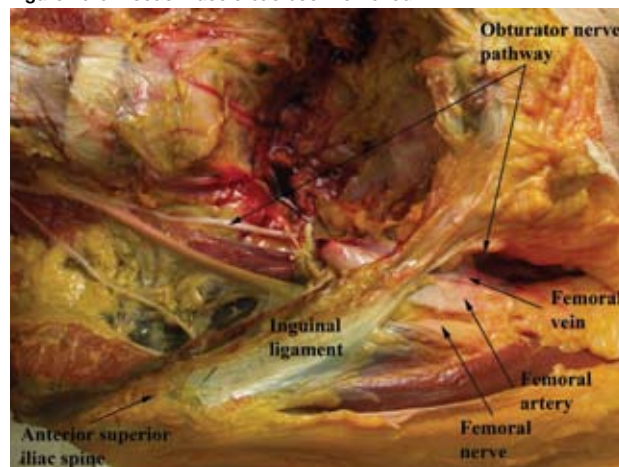
Figure 16-5. Dermatomes anesthetized with the obturator block (dark blue)



ramus), and divides into anterior and posterior terminal branches (Figure 16-6). The anterior branch supplies motor fibers to the anterior adductor muscles of the thigh as well as cutaneous fibers to the medial aspect of the thigh. The posterior branch, which lacks cutaneous fibers, supplies motor fibers to the deep adductor muscles of the thigh, as well as contributing to the innervation of the knee joint.

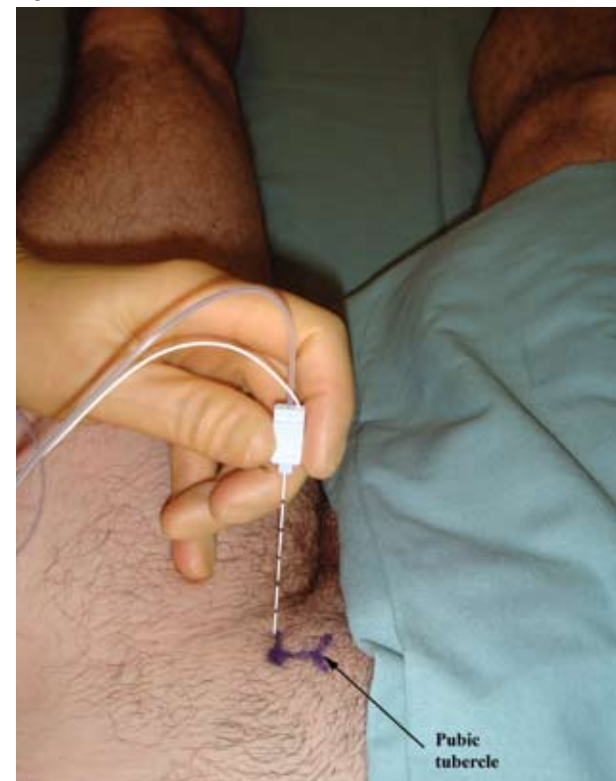**Procedure.** Set the nerve stimulator to 1.5 mA. Place the patient in the supine position with the thigh partially abducted and the knee partially flexed. Palpate the pubic tubercle, and draw a line 2 cm lateral and 2 cm inferior to the tubercle. Insert a 5- to 10-cm stimulating needle perpendicular to the skin until it contacts the pubic ramus. Then redirect it posteriorly and slightly laterally to “walk off” the needle from the pubic ramus and into the obturator foramen. When the adductor muscles twitch, gradually decrease the stimulator until the twitch is still visible at 0.5 mA or less. Inject 5 to 10 mL of local anesthetic (Figure 16-7).

Figure 16-6. Psoas muscle has been removed



**Teaching Point.** The obturator nerve is often not blocked when a femoral or fascia iliaca block is administered. For less invasive surgeries, such as diagnostic knee arthroscopies, this may not be a problem; however, for more invasive lower extremity surgeries such as total knee replacements, the obturator nerve must be included in the lumbar plexus block. When the obturator nerve must be blocked, either a posterior approach to the lumbar plexus is utilized, or, if a femoral block is used, the obturator nerve is anesthetized separately.

Figure 16-7





### Alternative Approach to the Obturator Nerve Block.

The anterior obturator branch supplies an articular branch to the hip and the anterior adductor muscles, and it provides cutaneous innervations to the lower medial aspect of the thigh. The posterior branch supplies the deep adductor muscles and often an articular branch to the knee joint. The accessory obturator nerve (L3 and L4) is present in a third of cases (8%–29% of human bodies) and sends a branch to the hip joint. When the accessory obturator nerve is not

present (71%–92% of cases), the posterior branch of the obturator nerve also sends a branch to the knee joint.

The inguinal interadductor obturator nerve block approach landmarks are the inguinal ligament, the femoral artery, and the long adductor muscle tendon. Draw a line immediately below the inguinal ligament from the medial edge of the femoral pulse to the medial border of the tendon of the long adductor muscle. Insert the needle at the midpoint of this line

(Figures 16-8 and 16-9). Insert a 21-gauge, 100-mm insulated needle slightly lateral and posterior, with a superior inclination. Carefully advance the needle until twitches of the anterior adductor muscles (anterior obturator branch) occur, and inject 5 to 7 mL of local anesthetic solution. Then advance the needle slowly a few millimeters in a slightly lateral direction until the posterior (major) adductor muscles twitch (posterior obturator branch), and inject another 5 to 7 mL of local anesthetic at this location.

Figure 16-8

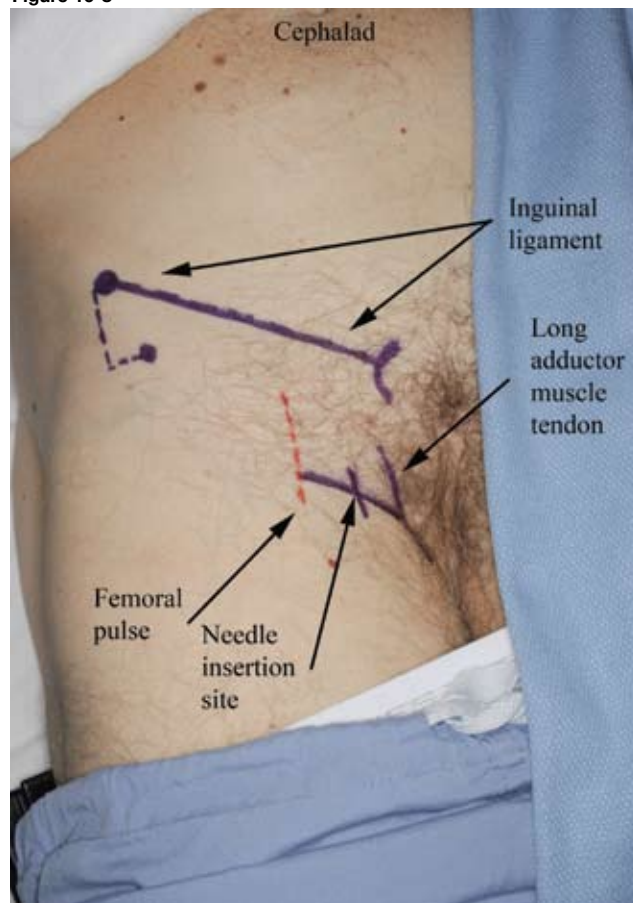


Figure 16-9

