

22. ANKLE BLOCK

INTRODUCTION AND ANATOMY

Five peripheral nerves supply the foot: the tibial nerve, the deep peroneal nerve, the superficial peroneal nerve, the sural nerve, and the saphenous nerve. All cross the ankle and are derived from the sciatic nerve except for the saphenous nerve, which is derived from the femoral nerve. The tibial and deep peroneal nerves supply deep structures of the foot and therefore must be blocked beneath the deep fascia of the ankle. The remaining nerves supply sensory innervation to the skin and can be blocked superficially (Figure 22-1). The ankle block works very well for foot and toe surgery and facilitates early ambulation.

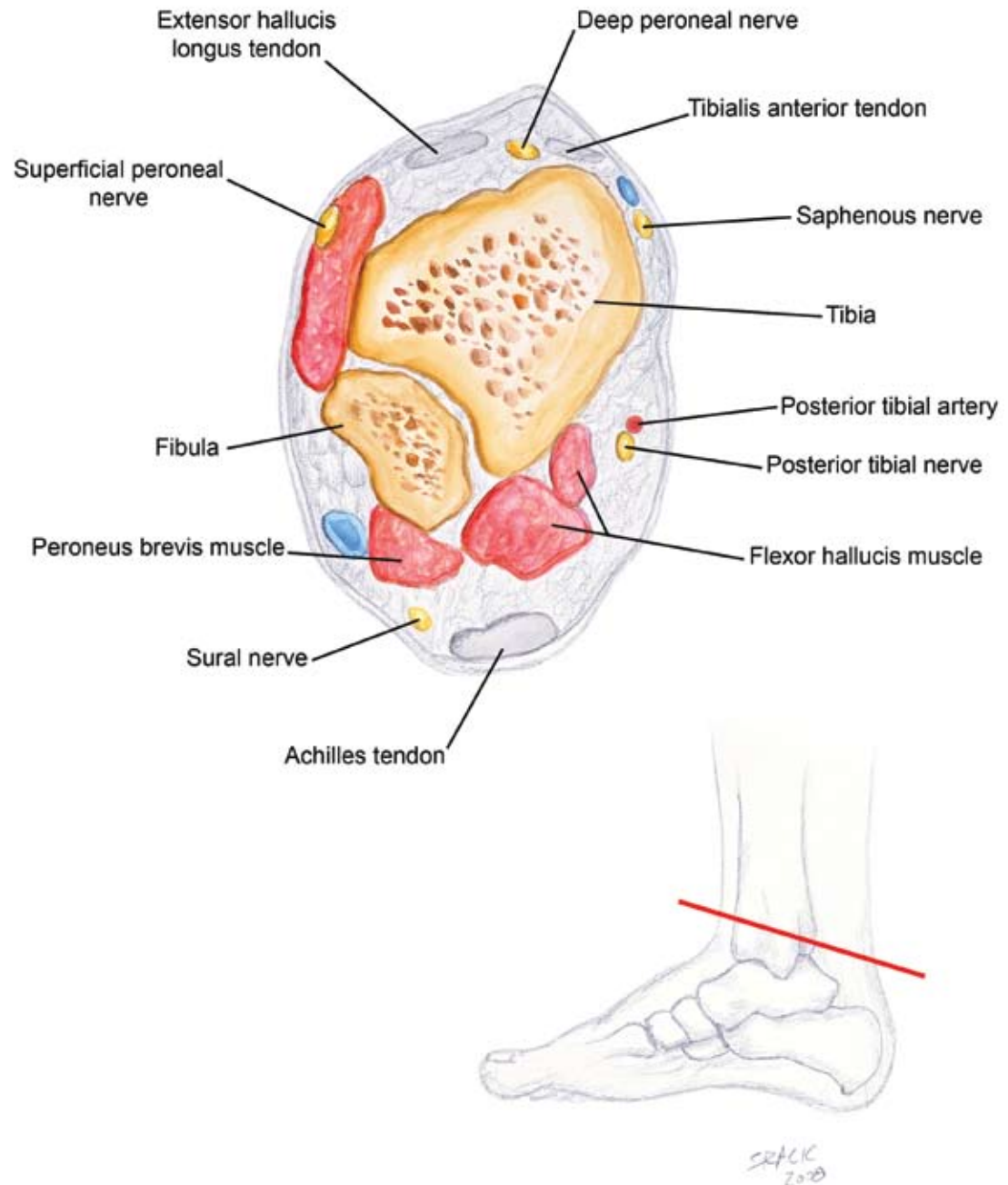


Figure 22-1

PROCEDURE

Landmarks

Tibial Nerve. This nerve is located posterior to the posterior tibial artery at the level of the medial malleolus. Palpate the artery and insert the needle passing posterior to the artery. A nerve stimulator can be used to help localize the nerve. The needle will typically contact the medial malleolus; after this contact occurs, slightly withdraw the needle. Inject 3 to 5 mL of local anesthetic (Figure 22-2).

Deep Peroneal Nerve. This nerve runs lateral to the dorsalis pedis artery at the level of the foot. Palpate the artery and insert the needle lateral to the artery. If bone is contacted, withdraw the needle slightly before injecting 2 to 4 mL of local anesthetic (Figure 22-3).

Superficial Peroneal Nerve. Inject a subcutaneous wheal of local anesthetic (5 mL) from the anterior border of the tibia to the lateral malleolus (Figure 22-4).

Figure 22-2

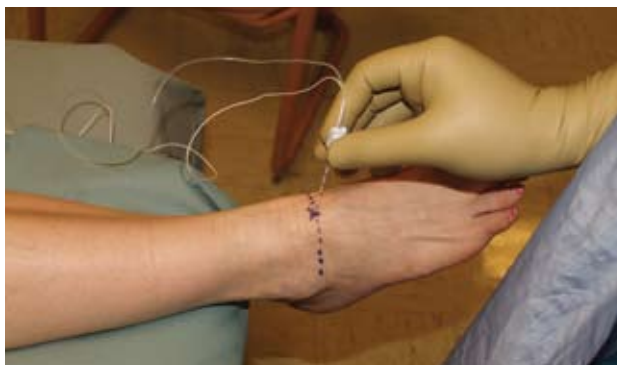
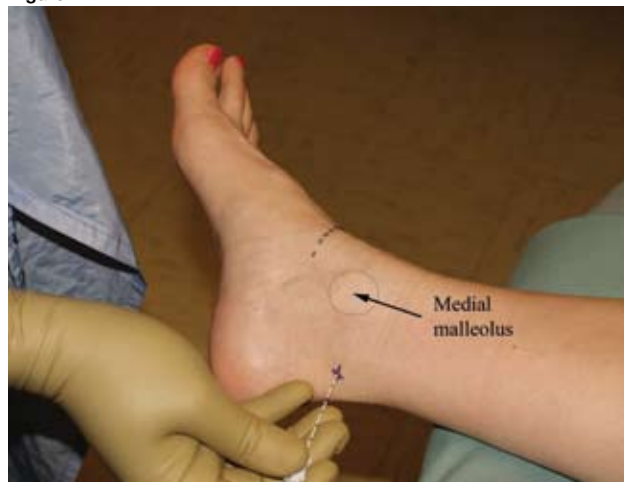
Figure 22-3

Saphenous Nerve. Inject a subcutaneous wheal of local anesthetic (5 mL), directing it posteriorly from the tibial ridge to the medial malleolus (Figure 22-5).

Sural Nerve. Insert the needle between the Achilles tendon and the lateral malleolus, and subcutaneously infiltrate 5 mL of local anesthetic along this course (Figure 22-6).

Needle. 22-gauge, 5-cm, b-bevel needle.

Figure 22-4

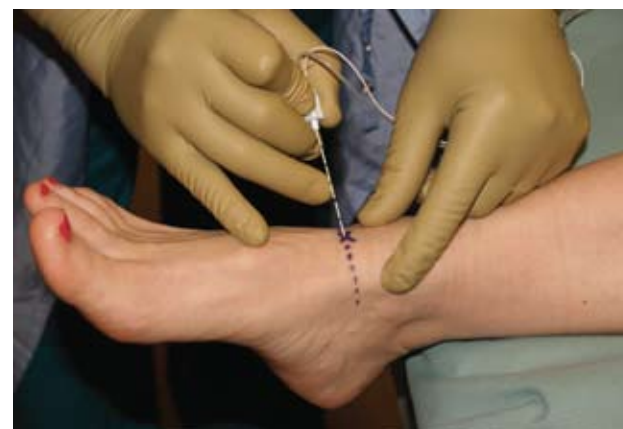
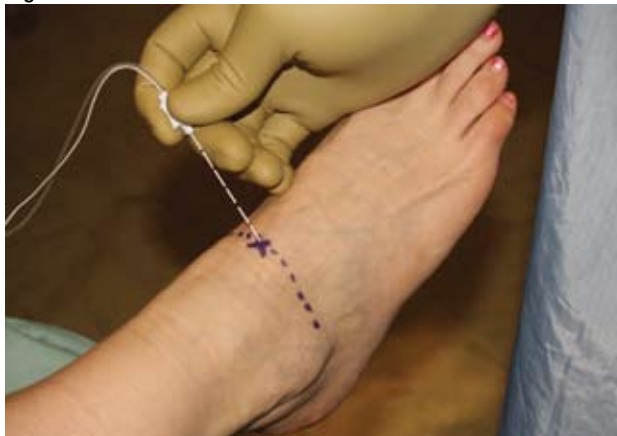
Figure 22-5

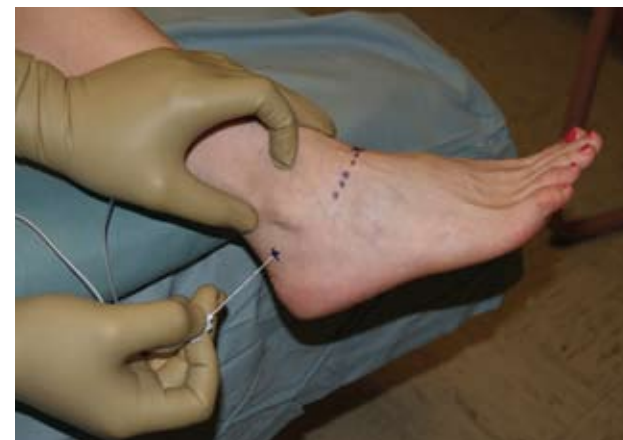

Figure 22-6

Teaching Points. Do not use epinephrine-containing local anesthetic for this block. If a paresthesia is elicited, the needle should be redirected prior to injection because intraneural injection can cause significant damage in these small nerves. Injection around the ankle can be uncomfortable; preemptive analgesia can be very helpful.